

“Every Contact Leaves Its Trace”-Insight into Recent Advances of Forensic Odontology

Sumalatha S.¹, Padmaja S.², Prafulla Thumati³

¹Department of Orthodontics & Orthopaedics, M.S.Ramaiah Dental College & Hospital, Bangalore, India

²Department of Prosthodontics, Bapuji Dental College and Hospital, Davangere, India

³Department of Prosthodontics, Dayananda Sagar College of Dental Sciences, Bangalore, India

Email address:

drpadma28@gmail.com (Padmaja S.), Drpadma7@yahoo.co.in (Padmaja S.)

To cite this article:

Sumalatha S., Padmaja S., Prafulla Thumati. “Every Contact Leaves Its Trace”-Insight into Recent Advances of Forensic Odontology. *Journal of Cancer Treatment and Research*. Vol. 3, No. 1, 2015, pp. 1-7. doi: 10.11648/j.jctr.20150301.11

Abstract: Forensic dentistry plays a major role in the identification of those individuals who cannot be identified visually or by other means. The unique nature of our dental anatomy and the placement of custom restorations ensure accuracy when the techniques are correctly employed. This article briefs an overview of some of the traditional and upcoming techniques in this fascinating field.

Keywords: Bite Mark, Lenticular card, Dental Profiling, CAHID, Memory Card, ALIAS, VCM, Mini STR

1. Introduction

Every day to day we come across violent and heinous activities that shatter the lives of victims, their friends and families. Often, little can be done to repair such damage. The apprehension and subsequent prosecution of the perpetrators is essential to maintain law and order. Sherlock Holmes remains a great inspiration for forensic science in literature, especially for the way his acute study of a crime scene yields small clues as to the precise sequence of events. He makes great use of trace evidence such as shoe and tire impressions, as well as fingerprints, ballistics and handwriting analysis. Through the speciality of forensic odontology, dentistry plays a small but significant role in this process. By identifying the victims of crime and disaster through dental records, dentists assist those involved in crime investigation. So what does Forensic odontology actually mean?

Forensic odontology is the study of dental applications in legal proceedings. The term “Forensic odontology” is derived from Latin, meaning forum or where legal matters are discussed. The subject covers a wide variety of topics including individual identification, mass identification, and bite mark analysis. Forensic dentistry or forensic odontology is the proper handling, examination and evaluation of dental evidence, which will be then presented in the interest of justice. The evidence that may be derived from teeth, is the age (in children) and identification of the person to whom the

teeth belong. This is done using dental records including radiographs, ante-mortem (prior to death) and post-mortem photographs and DNA.

Forensic dentists are responsible for six main areas of practice: 1) Identification of found human remains 2) Identification in mass fatalities 3) Assessment of bite mark injuries 4) Assessment of cases of abuse (child, spousal, elder) 5) Civil cases involving malpractice 6) Age estimation

Human teeth are the most durable bones in the body and can survive most physical trauma. This makes forensic odontologist an important person in the identification of human remains. In the forensics world, this applies to identifying unique traits of both deceased individuals and criminal suspects where tooth marks are evident. All dental records are based on a universal numbering system, and contain an amazing amount of information. For example, they note: 1. Fillings 2. Extractions 3. Surface structure/root configuration 4. Adjacent teeth 5. Twisted/tilted teeth 6. Ante mortem/Postmortem match determines identity.

HISTORY: The field of forensic dentistry is not new. The track of forensic dentistry goes as far back as 66 A.D. At the time of Nero 66 A.D, Lollia Paulina's body was identified using teeth. Paul Revere, was the first forensic dentist in the United States to identify a revolutionary soldier by means of a denture. From 66 A.D to recent years, dentists have played significant role in forensic odontology.

Theory behind Forensic Dentistry: The theory behind forensic dentistry is that no two mouths are alike (even

identical twins are different), and that teeth, like tools, leave recognizable marks. A bitemark, however, is not an accurate representation of the teeth. A lot depends on the mechanics of jaw movement and use of the tongue. Inside the mouth, the lower jaw (mandible) is movable and usually delivers the most biting force. The upper jaw (maxilla) is stationary, holding and stretching the skin, but when skin is ripped or torn, the upper teeth are involved more deeply. Most bitemarks usually show a curvature where the upper teeth, at least, made an impression.¹ The World Health Organization (WHO) distinguishes four types of violence; a) physical, b) sexual, c) psychological and d) neglect. All forms of violence can manifest in the oro-facial region, and are hence should be of concern to dentists. Injuries due to abuse can manifest in the oro-facial region in various forms, including fractured

anterior teeth, fractured alveolar bone, lacerations of the labial and buccal mucosae, lacerations to the frenum and bruises to the lips, face and neck.²

The initial goal of the forensic dentist is to obtain a set of postmortem photographs, radiographs, and accurate dental charting on the unidentified person. This can be a straightforward or difficult process, depending on the condition of the postmortem specimen and the physical resources available to the dentist.

2. An Orthodontic View

The following information can be taken from dental remains by Forensic Odontologist (table 1)

Table 1. Information obtained from Dental remains;

Information	Features
Deceased's Age	Reasonable estimates can be drawn from the development of the bones of the skull
Sex	From skull's shape and form: Males=larger skull with square orbits Females=smaller, round skull with minimal supra-orbital ridge and more vertical forehead
Socio-economic status	Quality / quantity and presence/absence of dental treatment may give identification
Occupation	e.g. carpenter leave characteristics groove by holding carpet pin between teeth
Dietary habits	e.g. high alcoholic consumption =erosion
Ancestry Background	Can determine race between 3 major groups-Caucasoid, Mongoloid, Negroid-from the skull's appearance.

The forensic odontologists should have their own kits containing necessary armamentarium (Table 2) for identification³:

Table 2. Suggested instrument kit for forensic identification

Dental explorers	Photographic mirrors
Dental mirrors	Periodontal probes
Bite blocks	Bone mallet
Tissue scissors	Camera
Osteotome	Head lamp
Rubber air / water syringe	Masks
Cotton swabs	Films
ABFO No.2 ruler	Stryker saw

Forensic Anthropology: it is the Identification and examination of skeletal remains which reveals personal attributes such as origin, sex, age, race, and/or injury. Facial reconstruction may be able to identify mass victims of disaster through skeletal remains

Age estimation: Age assessment using teeth provided the most reliable guide in the process of identification. Various methods are utilized which includes visual method, radiographic method, histological method, computer assisted method and comparison with ante mortem data. Eruption sequence, neonatal line formation, incremental lines of Retzius, Schour and Massler chart (to estimate dental age in developing dentition) and Gustafson's method are important parameters in age estimation.

Gustafson gave six points to determine the age estimation over 21 years. These include 1) attrition, 2) secondary dentin deposition, 3) position of periodontal attachment, 4) cementum deposition, 5) translucency at root and 6) root resorption.⁴ Further the examination of the mandible will help in assessing the age of the individual approximately.⁵ To

estimate age we can assess deposition of secondary dentin, pulp/root length, pulp/root width, pulp diameter to crown diameter ratio using periapical radiograph.⁶ The extent of racemization of aspartic acid in coronal dentin of normal permanent teeth can be used to estimate the age of an individual at the time of death. As age advances L aspartic acid will be converted into D aspartic acid.⁷ Recent studies provides the evidence that, the annual pattern of deposition of cementum on the surface of tooth roots can be used as a reliable age marker.⁸ Even the deepening of colour of tooth, intensity of fluorescence in dentine and cementum shows correlation between ages.⁹

Sex determination: Forensic dentists can assist other experts to determine sex of the remains by using teeth. Sex determined from necrotic pulp tissue stained by Quinacrine mustard for fluorescent Y chromosome. Fluorescent Y chromosome will be present in the teeth of males. Amelogenin or AMEL is a major protein in the human enamel which determines the sex of the remains¹⁰. The female has two identical AMEL genes whereas the male has two different AMEL genes.

Mass disasters: Comparison of ante mortem and postmortem radiographs is the most accurate and reliable method of identification in mass disaster identification¹¹. So for that, Disaster victim identification (DVI) teams are required to process the entire task in four main steps i.e., body tagging and bagging, finger printing, forensic pathology and forensic dentistry.

ROLE OF Saliva in Forensic Odontology: Early attempt should be made to collect saliva from bite marks for group tests. Saliva sample can be coupled with forensic DNA analysis to rule in or rule out the connection between an

individual and the forensic evidence Methylation, (which is a chemical change to one of the four building blocks of a person's DNA) changes as our bodies grow older, contributing to age related diseases. In extracting DNA from saliva samples, forensic investigation methodology can rule out strong correlation between methylation and age. Saliva tests can also reveal certain disease markers, viral infections, and the presence of therapeutic as well as illicit drugs in the body¹².

Bite mark analysis: Upon collection of dental evidence, the forensic odontologist analyzes and compares the bite marks. Studies have been performed in an attempt to find the simplest, most efficient, and most reliable way of analyzing bite marks. Factors that may affect the accuracy of bite mark identification include time-dependent changes of the bite mark on living bodies, effects of where the bite mark was found, damage on soft tissue, and similarities in dentition among individuals. Other factors include photography, impressions, or measurement of dentition characteristics.

Kouble and Craig¹³ compared direct methods and indirect methods of bite mark analysis.

- 1) Direct method: In this method, the model of suspects' teeth is compared to a life size photograph of the actual bite mark. Here direct comparison is made between dental models, photographs or finger print powder lift models. The "fingerprint powder lift" technique involves dusting the bitten skin with fingerprint powder and using fingerprint tape to transfer the bite marks onto a sheet of acetate.
- 2) Indirect methods: This method involves the use of transparent overlays to record a suspect's biting edges. Transparent overlays are made by free-hand tracing the occlusal surfaces of a dental model onto an acetate sheet. When comparing the "fingerprint powder lift" technique against the photographs, the use of photographs resulted in higher scores determined by a modified version of the American Board of Forensic Odontology (ABFO) scoring guidelines¹³. The use of transparent overlays is considered subjective because the tracing can be easily manipulated. On the other hand, photocopier-generated overlays where no tracing is used is considered to be the best method in matching the correct bite mark to the correct set of models without the use of computer imaging.

Computer Odontology: New advances in forensic science allow digital comparison of teeth and bitemarks at a 3-dimensional level which include:

- 1) Automatic dental code matching: In this, Bite marks are run through the computer to find a match
- 2) OdontoSearch: Compares a data base of missing peoples, felons, government workers
- 3) Automatic dental identification system will produce a list of people who have the same dental code number
- 4) 3D Bite mark analysis: 3D scans of dental casts are used to generate overlays using various pressure and deviation. The overlays are compared with the photograph of the bite marks. (Fig 1a & 1b)

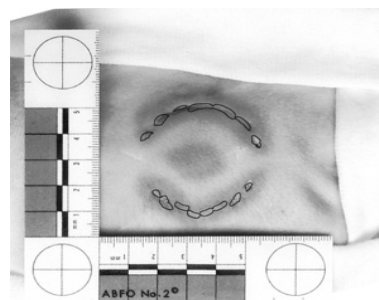


Fig 1a. Impression from teeth found on skin or items left at a scene, usually outline of teeth placement

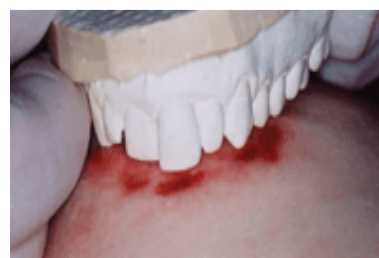

Fig 1b. Comparison between suspect cast and bite mark

Bite

marks: The occlusion of the teeth is an important factor in identifying the source of human bites found on the body of the victim requiring identification. Bite marks

can indicate the shape of the arch, missing teeth, and other peculiarities of the occlusion. For example: In a particular case, a partly-eaten apple proved to be an extremely important piece of evidence. The bite marks found in the apple helped one of an orthodontist to predict the killer's appearance. Bite mark analysis and analysis of occlusion revealed that the killer had a deformed jaw, large nose, high forehead, long thin face and an orthodontist confirmed that the killer would be tall and thin with a lantern jaw and may have breathing difficulties. The bite mark analysis confirmed suspect to be the killer and was punished for his role in a murder.

Other methods employed includes:

- a. RADIOGRAPHS
- b. PHOTOGRAPHS
- c. RUGOSCOPY :Study of Palatal Rugae
- d. AMELOGLYPHICS: Examination of Tooth Prints
- e. MOLECULAR METHODS (DNA Testing) :: Performs DNA profiling tests for Disputed Paternity, maternity Criminal Cases etc
- a) **Radiography in forensic odontology:** Dental radiographs like Orthopantomography (OPG), RVG (RadioVisioGraphy) and dental charting plays an excellent method for identification of dentition in detail which cannot be observed clinically. But, the comparison must be completed in a controlled and methodical manner, with attention to the details of the dental structures and restorations that may be seen in the radiographic comparison. Dental identification is most often accomplished by comparing postmortem dental

radiographs from the unidentified person with ante mortem radiographs of a known individual. This type of radiographic recording can be particularly useful in forensic odontology when trying to identify a person from certain selected indications or from a greater range of data¹⁴

Superimposition technique: In superimposition technique, photographs may be used to compare with the skull images or radiographs to reconstruct the face. Recently the electronic superimposition technique (photographic) are used as an adjunct to finger printing.¹⁵ While the photocopier-generated technique being sensitive, inexpensive and reliable, new methods involving digital overlays have proven to be more accurate. Use of Adobe Photoshop, 2D polyline and painting methods digitally analyse the bite marks. Use of the 2D polyline method entails drawing straight lines between two fixed points in the arch and between incisal edges to indicate the tooth width. Use of the painting method entails coating the incisal edges of a dental model with red glossy paint and then photographing the model. Adobe Photoshop is then used to make measurements on the image.^{16,17}

Cheiloscopy is the study of lip prints. Lip prints are normal lines and fissures in the form of wrinkles and grooves present in the zone of transition of human lip, between the inner labial mucosa and outer skin, probably unique to the individual in a manner similar to fingerprints. Lip print can be recorded using lipstick¹⁸ (Fig 2).

Lip print pattern (%)	Males (N=50x4)	Females (N=50x4)
Vertical	25 (12.5)	37 (18.5)
Branched	28 (14.0)	45 (22.5)
Intersected	79 (39.5)	73 (36.5)
Reticular	22 (11.0)	26 (13.0)
Undetermined	11 (5.5)	13 (6.5)
Poor quality	35 (17.5)	6 (3.0)

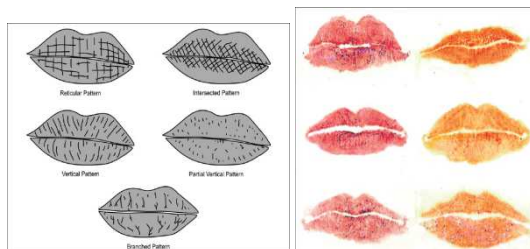


Fig 2. lip print pattern in males and females

Smile analysis: The dental analysis of the smile constitutes a current concern of specialties that include aesthetic dentistry. It established the importance of Diagrams of Dental Aesthetic Reference (DDAR), where a smile can reveal dental relationships of symmetry, dental axes, gum contours, inter-dental contacts, incisal edges, teeth proportions and smile lines.

Dental Profiling: When dental records are unavailable and other methods of identification are not possible, the forensic dentist can often produce a "picture" of the general features of the individual. This process is known as post-mortem dental profiling. A dental profile will typically provide

information on the deceased's age, ancestry background, sex and socio-economic status. In some instances it is possible to provide additional information regarding occupation, dietary habits, habitual behaviours and occasionally on dental or systemic diseases.

With the use of advanced technology like CAD/CAM/Rapid Prototyping, an Odontologist have also shown, in recent years, that it is possible to match DNA, Blood group antigens and tooth impression from a chewing gum retrieved from a crime scene. Thus "undermining the credibility of what has been considered the gold standard of proof in a crime"¹⁹.

3. A Prosthodontic View

More often, denture (full or partial) may be found within or close to the scene where the body is found. They can be useful aids in identification. The chances of identification of an edentulous person wearing dentures are less difficult in comparison to those of a dentate person. Hence, the labeled or marked dentures are most useful, for example: In April 1968, a badly mutilated body on the railway line at Mt. Kuringai near Sydney was positively identified as a patient of Parramatta Mental Hospital who had been missing for several weeks. The identification was made possible by an upper acrylic denture bearing a name inscribed on it.

Significance of Denture Labeling in Forensic Investigations²⁰⁻²² The denture marking is important for the following reasons:-

- It serves to identify an unknown denture wearer in cases involving amnesia or senility, loss of memory, psychiatric cases, homicide, suicide, victims of fire, explosion, floods, earthquake, plane crash, or war.
- In cases of lost and found, the denture can be returned to the owner.
- A rapid and accurate method other than finger printing is essential for identification of the individuals.
- In the laboratory, the dental technicians will find it easy to identify a denture, especially at the deflasking stage, if it is marked/labeled.
- To ensure the correct denture delivery to the respective patient.

The denture labeling should consist of name alone or along with other details like social security number, driver's license number, city code. Generally, a combination of name and identifying number used inside a denture provides great help and prevents misidentification or delay in identification. Unlike acrylic, Cobalt-chromium appliances resist melting even in some cases of incinerated remains. However, due to the hardness of the metal, it is not possible for dentists to mark cobalt-chromium appliances chair side. A new method for denture identification is *Lenticular card*: It is apolyethylene terephthalate, consisting of the first flip image of the patient's name, sex, and age, and a second flip image of his/ her address and driving license number, when viewed from a different angle can be inserted into an existing denture.²³

An all-acrylic resin appliance such as a full denture or an all-acrylic partial denture (or orthodontic appliance) could be marked with the patient's full name on a substrate (paper, metal) and sealed inconspicuously into the surface of a denture through various processes prior to delivery. Metal inserts from materials such as stainless steel orthodontic band, matrix band material, shim steel material, or aluminum can be used. It is recommended that an inclusion denture marker, preferably metallic, should be used in order to withstand the most common postmortem assaults.²⁴ In many cases of air disaster where the limbs are completely burnt off, some denture materials, especially the posterior part of acrylic dentures and metal-based dentures, outlast because of the tongue.²⁵⁻²⁶ Thus, marked dental prostheses (full and partial dentures, mouthguards, and removable orthodontic appliances) would lead to rapid identification in the event of accidents and disaster.

Denture Marking Using Memory Card: Recently the memory card can be programmed with all the relevant information regarding the patient identification, the photograph of the patient and wrap in cellophane, to be placed in polished surface of dentures (Fig 3). This method helps in easy identifying of both persons and dentures.²⁷

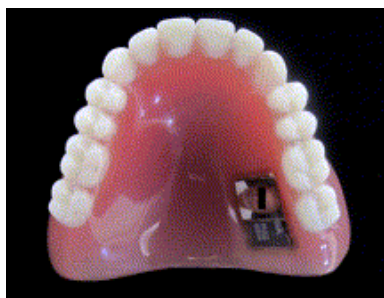


Fig 3. Denture marking using Memory card.

Rugoscopy is the study of palatal rugae. Rugae are amongst the best protected morphologically individualizing soft tissue structures in the body, which are preserved after death and yet accessible during life. Dental impressions are taken to record the rugae pattern.²⁸ Palatal rugae as an individualizing marker is highly reliable and user friendly, even on sub adults, where growth processes seem not to affect the specific morphology of palatal rugae. Palatal rugae represent a useful element for such a comparison, thanks to their apparent low variability with time and unique patterns.²⁹

Professor Sue Black, Director of the centre of Anatomy and Human Identification at the university of Dundee has started CAHID (the Centre of Anatomy and Human Identification). CAHID provides training and support for a variety of groups including international security and police organizations to help with disaster victim identification. Recently, the major incident team at Stanley Road Police Station in Liverpool has made a second call for dental professionals to check their records for evidence of contact with a gentleman named Paul John Morsan. Paul John Morsan, born 22 November 1979, was reported missing on 10th June 2011 having last been seen two days previously. A criminal investigation into his

disappearance is still underway.³⁰

Forensic dentistry in India has not yet caught on with the development with the other part of the globe because of low confidence seen in dentists when it comes to forensic cases, which may be due to inadequate training and exposure to advancements in this field.

The results of a survey³¹ conducted among the oral pathologists in India showed that there was low confidence among oral pathologists in handling forensic cases, because of inadequate formal training, minimal importance given to forensic dentistry in undergraduate/post graduate curriculum.

A three phase plan is recommended in the implementation of forensic science in India:

- 1) To conduct undergraduate program on pre-clinical forensic odontology with clinical training.
- 2) Structured program for post graduate training program in its specialities.
- 3) Certified courses/short-term courses/Diploma courses to be started in the speciality of forensic dentistry

4. The Future of Forensics

- There should be computer data base for all dental records to make access to records easier for those who need including Forensic Odontologists. All dental staff would need to be trained in uploading the information and how to use the new system like computer hardware and software to keep better and more up to.
- CAD-CAM systems are getting used more frequently in science and can be used in bite mark analysis. The computer system can be used to construct a 3D-image of an object that has been bitten into by scanning the object. This avoids any problems with impression taking which isn't always accurate and impression materials which even the best can distort. The CAD-CAM system stores all the information and can be used to "draw" up a picture of the dentition that made the bite. This computer system may not alone be 100% promising of the far results, it may be combined with the conventional methods to get best results.
- A new system that combine two and three-Dimensional technology into a hybrid product is more advanced than its forebears. Ex: Bullet Trax-3D and Brass Trax -3D systems.
- The Ballistics Analysis introduces ALIAS³² technology which is a relative newcomer to the forensic field. It consists of an enhanced Apple MacPro computer and an interferometer which measures variances as small as 2 microns (about 1/50 of a human hair) and creates a mathematical model or digital clone.
- It is difficult with the traditional microscope to achieve different views as it is time consuming in readjusting the focus and in achieving different views. Recently, Forensic technology has developed a prototype Virtual Comparison Microscope (VCM) which utilizes images of deformed bullets, bullet fragments and various types of rifling from the company's Bullet Trax-3D system. With the VCM, it is easy to find significant markings in any direction while maintaining a

consistent appearance.

- STR genotyping from degraded DNA samples requires genetic profiles to be obtained from DNA fragments as small as 100-200bp. With the use of Autosomic miniSTR Multiplex Genotyping, it is possible to obtain genetic profiling. These miniSTRs are smaller than the STRs used in standard typing.³³

5. Conclusion

Sherlock Holmes remains a great inspiration for forensic science in literature, especially for the way his acute study of a crime scene yields small clues as to the precise sequence of events. He makes great use of trace evidence such as shoe and tire impressions, as well as fingerprints, ballistics and handwriting analysis, now known as Questioned document examination. The most common site to be non-accidentally traumatized is the head. Therefore, injuries to the oro-facial region should raise reasonable suspicion to the treating dentist.

Suspicion should lead to investigation and reporting, but the reporting must be well-thought of. For dental identification to be successful, ante-mortem data need to be available. This relies heavily on dental professionals recording and keeping dental notes, radiographs, studymodels clinical photographs...etc. The availability of dental records will allow comparing the dental characteristics of the person during life with those retrieved from the person after death. Hence Forensic dentistry plays a major role in the identification of those individuals who cannot be identified visually or by other means. Depict glamorized versions of the activities of 21st-century forensic scientists. Some claim these TV shows have changed individuals' expectations of forensic science, an influence termed the "CSI effect".

References

- [1] Bowers, CM (2006). "Problem-based analysis of bitemark misidentifications: the role of DNA". *Forensic Science International* 159 Suppl 1: S104-9.
- [2] Mok JY. Non-accidental injury in children--an update. *Injury*. 2008 Sep; 39(9):978-85.
- [3] Neville. B., Douglas. D., Allen. C.M. and Bouquot, Textbook of Oral and Maxillofacial Pathology. 2nd Edn. Philadelphia (PA): WB Saunders Co., 2002: 763-783.
- [4] Burns. R., Maples. W.R., Estimation of age from individual adult teeth, *Journ of Foren. Scien* 1976; 21: 343-356.
- [5] Rao. V.S., Role of Forensic Odontologist in medico legal investigation, *Journ of Ind. Dent. Assoc* 1979; 51: 81-84.
- [6] Kvaal. S.I., Kolltveit. K.M., Thomsen, Age estimation of adults from dental radiographs, *Foren Sci. Inter* 1995; 74: 175- 185.
- [7] Ogino. T., Ogino. H and Nagy. B., Application of amino acid racemisation to Forensic Odontology – Postmortem designation of age at death, *Foren Sci Inter* 1989; 29: 259-267.
- [8] Renz, H; Radlanski, R (2006). "Incremental lines in root cementum of human teeth — A reliable age marker?" *HOMO – Journal of Comparative Human Biology* 57: 29.
- [9] Kvaal. S and Solhiem. T., Fluorescence from dentin and Cementum in human mandibular second premolars in relation to age, *Scand. J Dent. Res* 1989; 97: 131-138.
- [10] Whittaker. D.K., Llewelyn. D.R and Jones. R.W., Sex determination from necrotic pulp tissue, *Brit. Dent. Journ* 1975; 139: 137-139.
- [11] Murphy. W.A., Spruill. F.G and Gantner. G.E., Radiologic identification of unknown human remains, *Journ of Foren Sci* 1980; 25: 727-735.
- [12] *Journal of the Forensic Science Society, Volume 14, Issue 3, July 1974, Pages 241-245.*
- [13] Kouble RF, Craig GT. (2004). "A comparison between direct and indirect methods available for human bite mark analysis". *Journal of Forensic Science* 49 (1): 111-118.
- [14] Contribution of pantomography to forensic odontology Original Research Article *Forensic Science, Volume 9, 1977, Pages 13-20*
- [15] Whittaker. D.K., Richards B.H. and Jones. M.L., Orthodontic reconstruction in a victim of murder, *Brit Journ of Ortho* 1998; 25: 11-14.
- [16] Al-Talabani N, Al-Moussawy, ND, Baker FA, Mohammed HA (2006). "Digital analysis of experimental human bitemarks: application of two new methods". *Journal of forensic sciences* 51 (6): 1372-5.
- [17] Martin-de las Heras S, Valenzuela A, Valverde AJ, Torres JC, Luna-del-Castillo JD (2007). "Effectiveness of comparison overlays generated with DentalPrint software in bite mark analysis". *Journal of forensic sciences* 52 (1): 151-6.
- [18] Suzuki. K., Tsuchiahahi. Y., Two criminal cases of lip print, *Crimin Japn* 1975; 41: 61-64.
- [19] Blackwell SA, Taylor RV, Gordon I, et al., 3-D imaging and quantitative comparison of human dentitions and simulated bite marks. *Int J Legal Med.* 2007 Jan; 121(1):9-17.
- [20] Brannon RB, Kessler HP. Problems in mass disaster dental identification a retrospective review. *J Forensic Sci.* 1999; 44: 123-7.
- [21] Woodward JD. Denture marking for identification. *J Am Dent Assoc.* 1979; 99: 59-60.
- [22] Haines DH. Identification in mass disasters from dental prosthesis. *Int J Forensic Dent.* 1973; 1: 11-5.
- [23] Colvenkar SS. Lenticular card: A new method for denture identification. *Indian J Dent Res* 2010; 21: 112-4
- [24] Richmond R, Pretty IA. Contemporary methods of labeling dental prostheses—a review of the literature. *J Forensic Sci.* 2006; 51: 1120-6.
- [25] Haines DH. Identification in mass disasters from dental prostheses. *Int J Forensic Dentist.* 1973; 1: 11-15.
- [26] Friedman RB, Cornwell KA, Lorton L. Dental characteristics of a large military population useful for identification. *J Forens Sci.* 1989; 6: 1357-64.

- [27] Reena Luthra, Saryu Arora et al: Denture Marking for Forensic Identification Using Memory Card: An Innovative Technique: The Journal of Indian Prosthodontic Society : December 2012, Volume 12, Issue 4, pp 231-235
- [28] Kapali. S., Townsend. G., Richard. L. and Parish. T: Palatal rugae patterns in Australian Aborigines and Caucasians, Austr. Dent. Journ 1997; 42: 129-133.
- [29] Palatal rugae as an individualising marker: Reliability for forensic odontology and personal identification Original Research Article Science & Justice, Volume 52, Issue 3, September 2012, Pages 181-184
- [30] Morgue campaign on Crime writer: British Dental Journal Vol 121, no 11, June 9 2012 page 523-24.
- [31] Pushparaja shetty et al Forensic Odontology in India, an oral pathologist's perspective; J Forensic Dent Sci 2011 Jan-Jun 3(1) 23-26.
- [32] Dale Garrison: Recent Advances in Forensic Ballistics: evidence magazine.com
- [33] Robert E. Barsley: A look at Forensic Odontology 2/2007.